Proximal Rectus Femoris Tendon Tear in a Professional Football Placekicker: A Case Report

Kayle Noble-Taylor, DO;[1,2] Mark Price, MD, PhD;[2,3] and Kelly McInnis, DO[1,2]

Introduction

The rectus femoris (RF) is the most superficial quadriceps muscle. It acts as a hip flexor and knee extensor (1). Proximally, it has two tendon origins, the direct head attachment to the anterior inferior iliac spine (AIIS) and the indirect head attachment to the hip joint capsule at the superior acetabular ridge (Fig. 1) (2). The two heads come together to form a conjoined tendon with the direct head fibers forming the superficial component and indirect head fibers forming the deep component (1).

The RF is the quadricep muscle most prone to injury given its biarticular nature. Injuries frequently result from a kicking or sprinting mechanism and are common in sports, such as football and soccer (3–6). Injuries often occur at the musculotendinous junction (2).

AIIS tendon avulsion injuries of the RF direct head are documented, but relatively uncommon (7,8). Proximal RF tears involving both the direct and indirect heads are even less frequently encountered (7,9). There are two prior cases in National Football League (NFL) punters who also performed placekicking duties with a similar mechanism and location of injury, but no cases of pure placekickers. This case describes the clinical features, management, and return to sport of a proximal RF tendon tear in a professional American style football placekicker.

Case Report

History

A 23-year-old right-leg dominant male professional, American style football placekicker presented with a 10-d history of right hip pain after sustaining a noncontact injury in practice. He felt a right anterior hip region clicking sensation while getting off an exercise bike. He then immediately went out to practice. After several nonpainful practice kicks, he had significant sudden-onset pain when his hip was in the extreme of the extension, with ball strike, and follow-through. He was not able to continue practice. After the injury, he experienced right quadriceps weakness and pain with walking and hip flexion. He denied swelling, ecchymosis, paresthesias, mechanical symptoms, recent injury, or change in training regimen. He was a soccer-style placekicker.

Physical Examination

There was a visible soft tissue defect at the anterior proximal thigh with quadriceps contraction and single-leg stance, which was tender to palpation. There was no evidence of edema or ecchymosis. Hip flexion was limited to 100 degrees secondary to pain. Otherwise, hip range of motion was full, but painful. Neurovascular examination was intact with full strength with hip flexion and knee extension. Intra-articular hip provocative maneuvers were negative. Single-leg squat was difficult to perform secondary to pain.

Imaging

Point-of-care musculoskeletal ultrasound of the right hip region revealed near-complete musculotendinous disruption of the RF direct head tendon with interposing hemorrhage of variable echogenicity and approximately 1 cm of retraction (Fig. 2A, B). The RF indirect head was poorly visualized on ultrasound. There was no increase in retraction with dynamic ultrasound quadriceps activation.

Right hip magnetic resonance imaging (MRI) revealed a high-grade, near full-thickness partial tear of the direct and indirect attachments the RF with corresponding intramuscular edema (Fig. 2C, D).

Diagnosis

Right proximal RF near complete tendon tear with 1 cm retraction of direct head and subtotal tear of indirect head with no considerable retraction.

Outcome

The athlete received our team opinion regarding the risks and benefits of both nonoperative care and surgical repair. He also sought a second surgical opinion with an outside hip specialist. He elected to undergo an open RF tendon repair 2 wk after the injury with the outside hip specialist.

[1]Department of Physical Medicine and Rehabilitation, Harvard Medical School, Spaulding Rehabilitation Hospital, Charlestown, MA; [2]Division of Sports Medicine, Harvard Medical School, Massachusetts General Hospital, Boston, MA; and [3]Department of Orthopedic Surgery, Harvard Medical School, Massachusetts General Hospital, Boston, MA

Address for correspondence: Kayle Noble-Taylor, DO, 300 First Avenue, 2nd Floor, Charlestown, MA 02129; E-mail: knobletaylor@partners.org.

1537-890X/2206/187–190
Current Sports Medicine Reports
Copyright © 2023 by the American College of Sports Medicine

Copyright © 2023 by the American College of Sports Medicine. Unauthorized reproduction of this article is prohibited.

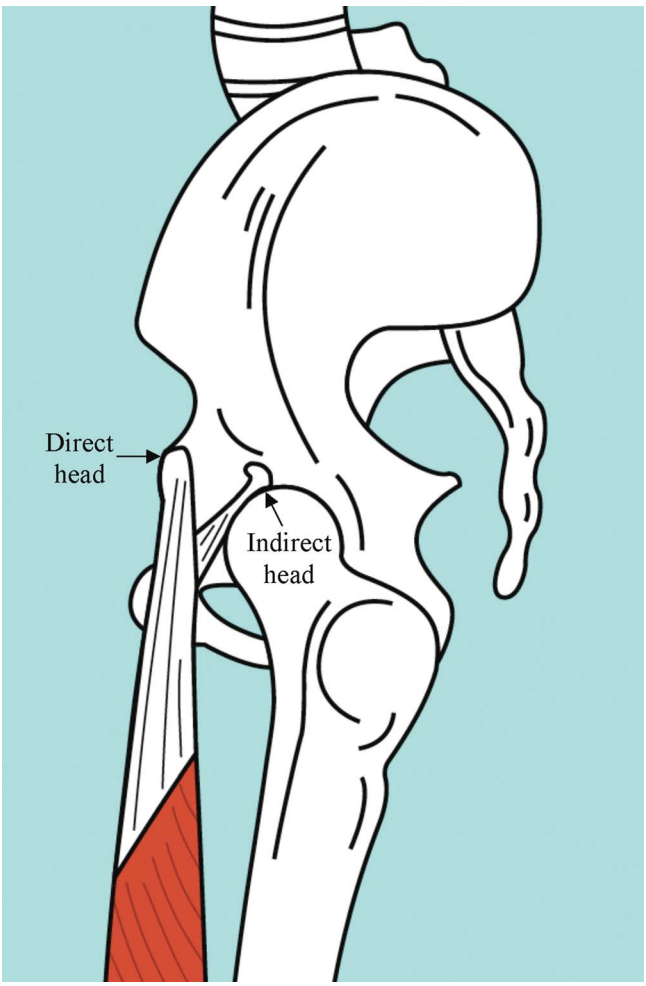

Figure 1: Illustration of a left sagittal hemipelvis demonstrating the two RF tendon origins, the direct head attachment to the AIIS and the indirect head attachment to the hip joint capsule at the superior acetabular ridge.

Return to Activity

Following surgery, the patient underwent a graduated rehabilitation program as directed by his surgical team. He was non–weight-bearing for 6 wk postoperative. Physical therapy began at 4 wk focused on hip motion progressing to isometric strengthening followed by eccentric strengthening at 8 wk. Return to kicking began at 3 months. At 6 months, he had a minor strength deficit with hip flexion compared with the noninjured leg but had returned to running and kicking pain-free.

Discussion

Proximal RF tendon injuries frequently result from kicking mechanisms (3,5,6,10). The backswing of a kick, when the hip is hyperextended and knee is flexed, places significant tension on the RF. The terminal backswing involves a forceful eccentric contraction placing the RF tendon at high risk of injury (11). There is limited data regarding intrinsic and extrinsic factors that may play a role in proximal RF tendon injury, but there is some evidence to suggest decreased quadriceps flexibility and strength in addition to playing on a dry field surface may put players at risk (4,12).

Diagnosis of RF tendon injuries is typically made clinically based on mechanism of injury and physical examination. MRI is the criterion standard imaging modality for confirming the diagnosis and defining tendon injury characteristics, as in the presented case (13). Musculoskeletal ultrasonography (US) is a useful diagnostic point-of-care tool, especially when there is edema or hematoma, and can assist in monitoring the recovery of RF injuries (14). However, imaging of the RF indirect head, given its oblique path to the acetabulum, is challenging, even for experienced musculoskeletal sonographers. Plain radiographs may be useful to rule out associated bone avulsion injuries, especially in the skeletally immature athlete.

Characteristic MRI grading of myotendinous injury ranges from I to III (13,15). Grade I tears are defined by high-intensity signal at an intact myotendinous junction. Grade II tears are defined by partial disruption of the myotendinous junction. Grade III tears involve complete myotendinous disruption with or without retraction (11,13). A newer grading system proposed by British Athletics describes a more detailed classification based on extent (grades 0 to 4) and site of injury (a, myofascial; b, muscular/musculotendinous; c, intratendinous) (15,16). Based on this system, this case illustrates a grade 3c, near complete intratendinous tear with retraction.

Proximal RF tendon tears are typically managed nonoperatively. This includes an initial rest period (usually 3 to 5 d) that may involve crutches if ambulation is painful. Pain is managed with ice, modalities, and analgesic medications. This is followed by a comprehensive rehabilitation protocol involving therapeutic exercise, including core stability, isometric progressing to eccentric and concentric strengthening of the hip flexors and knee extensors, and stretching of the iliopsoas and quadriceps musculature (11). Graduated return to sport- and position-specific exercise is performed. Return to sport is appropriate when the athlete's pain is controlled with near normal hip range of motion and strength compared with the contralateral side.

The use of platelet-rich plasma (PRP) to augment proximal RF tendon healing has been described in a case report of a recreational soccer player with MRI evidence of a partial direct head and complete indirect head tear who underwent three US-guided PRP injections at 10, 20, and 30 d with concurrent rehabilitation (isometric progressing to eccentric exercises) (17). Pain and hip flexion strength deficits improved at 45 d (17). PRP composition and return to sport were not described. Further research is needed to assess PRP outcomes in augmenting proximal RF healing and how this may impact return to sport in the elite athlete.

Surgery is reserved for high-level athletes with complete tears involving the direct and indirect heads or incomplete tears that fail nonoperative management. The procedure involves resection of the proximal tendon remnants followed by myotendinous suture anchor repair to the AIIS. (18) Postoperative rehabilitation has been described in professional soccer players and is prolonged compared with nonoperative management (12 to 30 wk compared with 6 to 12 wk). It includes use of crutches (weeks 1 to 2), pool training (weeks 3 to 4), cycling and weight training (weeks 8 to 12), kicking/sprinting (weeks 12 to 24), and full return to play (weeks 12 to 30) (18). Several prior studies in professional soccer report the ability to return to preinjury level of competition after operative intervention (18–21).

Prior reports of professional, American style football kickers with proximal RF tendon injuries are limited. A report of two

Copyright © 2023 by the American College of Sports Medicine. Unauthorized reproduction of this article is prohibited.

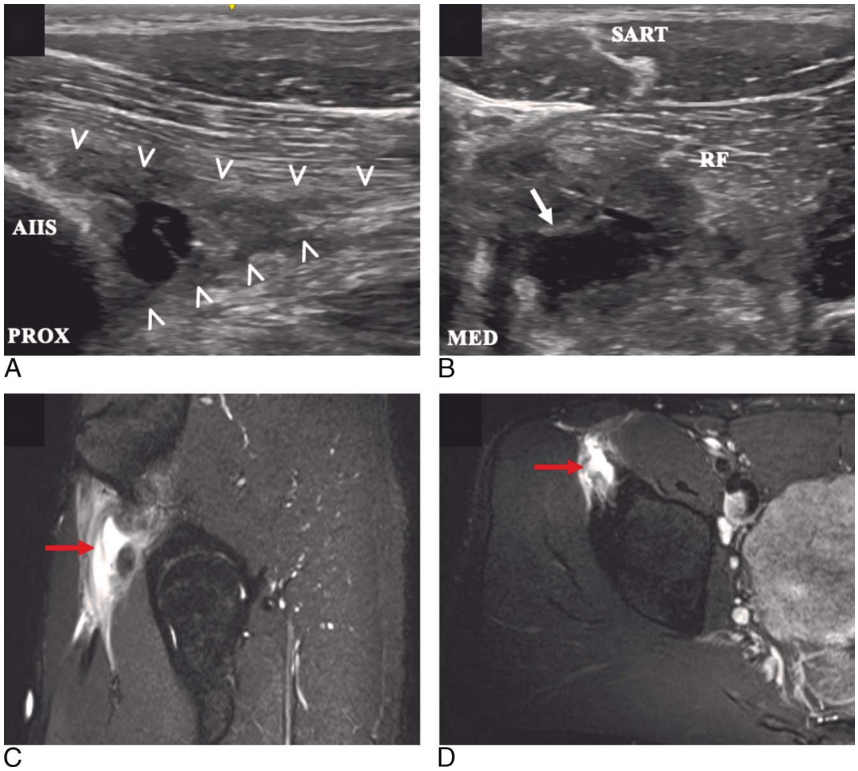

Figure 2: Point-of-care musculoskeletal ultrasound of the right hip region with the RF direct head tendon (white arrowheads) in (A) long axis and (B) short axis demonstrating nearly complete musculotendinous disruption of the RF direct head with interposing hemorrhage of variable echogenicity (white arrow) and approximately 1 cm of retraction. Right hip MRI (C) T2-weighted sagittal image and (D) T2-weighted axial image revealing a high-grade near full-thickness partial tear of the direct and indirect attachments of the RF with corresponding fluid-filled gap and intramuscular edema (red arrows). PROX, proximal; SART, sartorius.

cases in NFL punters who also performed placekicking duties described similar mechanisms of injury compared with this case with one injury occurring during a kick in practice and the second in a game (8). MRI demonstrated grade 4 complete avulsions of the RF direct tendon head in both cases (8). Unlike this case, both athletes were managed nonoperatively with return to game participation in 4 and 7 wk, respectively (8). Furthermore, a case series of proximal RF complete avulsions in 11 NFL athletes (two punters, nine position players, no pure placekickers) describes successful nonoperative management with return to play in 6 to 12 wk (7,8). There is a paucity of evidence describing operative management of proximal RF tendon tears in professional, American style football kickers, especially placekickers.

Conclusion

Proximal RF tendon injuries are rare, especially those involving both the direct and indirect tendon heads. This case adds to a limited body of literature describing proximal RF tendon injuries in elite athletes. It highlights that operative management can lead to successful return to pain-free kicking in this population. As successful return to play also has been described with nonoperative care involving focused rehabilitation, decision making can be challenging in the elite athlete with several factors influencing the discussion, including injury timing, athlete's career stage and goals. Shared decision making is required to determine the best treatment path. Further research is necessary to better predict outcomes for recovery and return to play in the elite level kicking athlete.

The authors declare no conflict of interest and do not have any financial disclosures.

Approval for this study was deemed exempt from the Mass General Brigham Institutional Review Board (IRB) and was approved through the NFL-NFL Players Association (NFLPA) Player Scientific and Medical Research Approval Process. Mack C, Matava M, Zeidler K, et al. Clinical Research in the National Football League: The Player Scientific and Medical Research Protocol. *Curr Sports Med Rep*. 2020 May;19(5):168-174.

References

1. Gyftopoulos S, Rosenberg ZS, Schweitzer ME, Bordalo-Rodrigues M. Normal anatomy and strains of the deep musculotendinous junction of the proximal rectus femoris: MRI features. *AJR Am. J. Roentgenol*. 2008; 190:W182–6.
2. Pesquer L, Poussange N, Sonnery-Cottet B, *et al*. Imaging of rectus femoris proximal tendinopathies. *Skeletal Radiol*. 2016; 45:889–97.
3. Ekstrand J, Hägglund M, Waldén M. Epidemiology of muscle injuries in professional football (soccer). *Am. J. Sports Med*. 2011; 39:1226–32.
4. Woods C, Hawkins R, Hulse M, Hodson A. The football association medical research Programme: an audit of injuries in professional football - analysis of preseason injuries. *Br. J. Sports Med*. 2002; 36:436–41; discussion 441.
5. Ekstrand J, Hägglund M, Waldén M. Injury incidence and injury patterns in professional football: the UEFA injury study. *Br. J. Sports Med*. 2011; 45:553–8.
6. Inklaar H. Soccer injuries. I: incidence and severity. *Sports Med*. 1994; 18: 55–73.

Copyright © 2023 by the American College of Sports Medicine. Unauthorized reproduction of this article is prohibited.

7. Gamradt SC, Brophy RH, Barnes R, *et al*. Nonoperative treatment for proximal avulsion of the rectus femoris in professional American football. *Am. J. Sports Med*. 2009; 37:1370–4.
8. Hsu JC, Fischer DA, Wright RW. Proximal rectus femoris avulsions in National Football League kickers: a report of 2 cases. *Am. J. Sports Med*. 2005; 33: 1085–7.
9. Park CK, Zlomislic V, Du J, *et al*. Nonoperative management of a severe proximal rectus femoris musculotendinous injury in a recreational athlete: a case report. *PM R*. 2018; 10:1417–21.
10. Geiss Santos RC, van Hellemnondt F, Yamashiro E, *et al*. Association between injury mechanisms and magnetic resonance imaging findings in rectus femoris injuries in 105 professional football players. *Clin. J. Sport Med*. 2022; 32: e430–5.
11. Mendiguchia J, Alentorn-Geli E, Idoate F, Myer GD. Rectus femoris muscle injuries in football: a clinically relevant review of mechanisms of injury, risk factors and preventive strategies. *Br. J. Sports Med*. 2013; 47:359–66.
12. Fousekis K, Tsepis E, Poulmedis P, *et al*. Intrinsic risk factors of non-contact quadriceps and hamstring strains in soccer: a prospective study of 100 professional players. *Br. J. Sports Med*. 2011; 45:709–14.
13. Boutin RD, Fritz RC, Steinbach LS. Imaging of sports-related muscle injuries. *Radiol. Clin. North Am*. 2002; 40:333–62.
14. Paoletta M, Moretti A, Liguori S, *et al*. Ultrasound imaging in sport-related muscle injuries: pitfalls and opportunities. *Medicina (Kaunas)*. 2021; 57:1040.
15. Pollock N, James SL, Lee JC, Chakraverty R. British athletics muscle injury classification: a new grading system. *Br. J. Sports Med*. 2014; 48:1347–51.
16. Patel A, Chakraverty J, Pollock N, *et al*. British athletics muscle injury classification: a reliability study for a new grading system. *Clin. Radiol*. 2015; 70: 1414–20.
17. Pogliacomi F, Visigalli A, Valenti PG, *et al*. Rectus femoris myotendinous lesion treated with prp: a case report. *Acta Biomed*. 2019; 90(12-S):178–83.
18. Lempainen L, Kosola J, Pruna R, *et al*. Operative treatment of proximal rectus femoris injuries in professional soccer players: a series of 19 cases. *Orthop. J. Sports Med*. 2018; 6:2325967118798827.
19. García VV, Duhrkop DC, Seijas R, *et al*. Surgical treatment of proximal ruptures of the rectus femoris in professional soccer players. *Arch. Orthop. Trauma Surg*. 2012; 132:329–33.
20. Sonnery-Cottet B, Barbosa NC, Tuteja S, *et al*. Surgical management of rectus femoris avulsion among professional soccer players. *Orthop. J. Sports Med*. 2017; 5:2325967116683940.
21. Ueblacker P, Müller-Wohlfahrt HW, Hinterwimmer S, *et al*. Suture anchor repair of proximal rectus femoris avulsions in elite football players. *Knee Surg. Sports Traumatol. Arthrosc*. 2015; 23:2590–4.

Copyright © 2023 by the American College of Sports Medicine. Unauthorized reproduction of this article is prohibited.